

# Development of a Structurally Optimized Polycarbonate Assistive Device for Pelvic and Lower Extremity Radiography with Potential Application in MRI-Compatible Environments

Hyeonggyun Kim and Dayeong Hong\*

*Department of Radiological Science, Gimcheon University, Gimcheon, Gyeongsangbuk-do, 39528, Republic of Korea*

(Received 6 November 2025, Received in final form 17 December 2025, Accepted 18 December 2025)

**This study aimed to design and fabricate a structurally optimized, multi-angle adjustable assistive device made of lightweight polycarbonate to improve posture reproducibility and image quality in pelvic and lower extremity X-ray examinations. To evaluate its educational and clinical efficiency, the device was applied in both radiologic science training and clinical imaging environments. With the application of the device, the practical performance skills of radiologic science students improved by 44%, while satisfaction and confidence increased by 25.4%. In clinical imaging, the device demonstrated a 1.5% improvement in alignment accuracy, a 40% reduction in the number of exposures, and enhanced pelvic alignment accuracy. These results indicate that the proposed assistive device contributes to standardized radiographic positioning and improved imaging efficiency. Furthermore, due to the non-magnetic nature of the polycarbonate material, the device shows potential applicability in MRI-compatible and magnetically sensitive clinical environments, supporting its broader clinical utility.**

**Keywords :** non-magnetic polymer, magnetic field compatibility, structural optimization, MRI safety, radiographic positioning

## 1. Introduction

Because human morphology varies widely across individuals, patient positioning and beam angulation during radiographic examinations play a decisive role in both diagnostic accuracy and image quality [1, 2]. In pelvic and lower extremity radiographs, maintaining a stable and standardized posture directly influences the diagnostic utility of the image while also affecting gonadal dose during X-ray exposure, thus warranting meticulous attention to radiation protection principles [3, 4]. For these reasons, the development of auxiliary devices that facilitate reproducible alignment and precise control of anatomical angles has emerged as a priority, with the aim of enhancing both image quality and radiation protection [5, 6].

Conventional radiography of the pelvis and lower extremities is a fundamental—and often indispensable—imaging modality in the diagnostic workup of musculo-

skeletal disorders [7, 8]. Previous studies have reported that patient positioning and angle setting in pelvic and lower extremity X-ray examinations have a significant impact on image quality and diagnostic accuracy, with most research focusing on improvements in imaging protocols or enhancements in examiner proficiency [9, 10]. In addition, although auxiliary approaches aimed at standardizing radiographic techniques and improving workflow efficiency have been proposed, limitations remain in the development of structural assistive devices that simultaneously consider both educational and clinical environments [11]. Existing radiographic positioning aids are largely limited to fixing specific postures or providing simple support, which restricts opportunities for learning multi-angle adjustment and anatomical alignment that reflect real clinical situations. Consequently, there is a growing need for the development of structurally and functionally optimized assistive devices that can be stably applied in both educational and clinical environments [12]. Based on this background, the purpose of this study is to develop a dedicated assistive device for pelvic and lower extremity X-ray examinations by addressing the structural limitations of existing positioning aids, and to

---

©The Korean Magnetism Society. All rights reserved.

\*Corresponding author: Tel: +82-54-420-4244

Fax: +82-54-420-4003, e-mail: dyhong.89@gmail.com

comprehensively evaluate its potential to improve image quality, workflow efficiency, and learning outcomes through application in both educational and clinical environments.

## 2. Materials and Methods

### 2.1. Study Design and Fabrication of the Auxiliary Device

This investigation was designed as an experimental study involving the development and fabrication of a structurally optimized auxiliary device for standardized pelvic and lower extremity radiography, followed by an evaluation of its educational and clinical utility. The primary objective was to improve positional reproducibility and workflow efficiency during routine X-ray examinations. The device was purposefully developed to address structural limitations identified in auxiliary positioning aids currently used at a general university hospital, with iterative refinements focused on accurate posture replication, simplified setup procedures, and reliable application in both educational laboratories and clinical settings.

As illustrated in Fig. 1, the device was designed using three-dimensional (3D) modeling with Autodesk Inventor Professional 2024. The design constraints ensured proper alignment of the biomechanical axes of the pelvis and lower extremities while maintaining coincidence with the X-ray central beam. In addition, the structure incorporated subject-specific, angle-adjustable components to accommodate variations in body habitus. To achieve portability, durability, and radiographic compatibility, both the frame and patient-contact components were fabricated from lightweight, transparent, radiolucent, nonmetallic polycarbonate. Based on the finalized design drawings, four individual components were precision-machined using computerized numerical control (CNC) milling and subsequently assembled to satisfy the specified dimensional tolerances.

### 2.2. Efficiency Evaluation of the Auxiliary Device

The efficiency of training outcomes and clinical image quality was evaluated using a before–after study design, comparing a pre-implementation control cohort without the device with a post-implementation experimental cohort utilizing the developed auxiliary device.

#### 2.2.1. Evaluation of Learning Outcomes

Learning effects associated with device use were assessed in 15 undergraduate radiography students (eight male, seven female) enrolled in the radiologic science practicum who voluntarily consented to the study procedures. During training focused on accurate reproduction of positioning for pelvic radiography, students completed exercises under two conditions: (i) without the auxiliary device (control) and (ii) with the auxiliary device (experimental). Learning effectiveness under each condition was then assessed and compared.

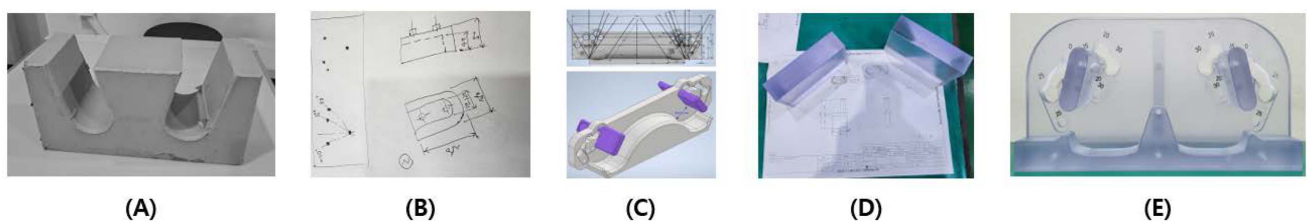
As shown in Table 1, Questionnaire-based assessment was employed, with items categorized into the cognitive, psychomotor, and affective domains to evaluate learning achievement across these dimensions.

Items in the cognitive domain were scored on a 2-point scale, whereas items in the psychomotor and affective domains used a 5-point Likert scale, ranging from 1 (“Strongly Disagree”) to 5 (“Strongly Agree”). The survey items and scores are presented in detail in Table 1.

#### 2.2.2. Clinical Applicability Assessment

Clinical efficiency was evaluated using anteroposterior (AP) pelvic radiographs obtained preoperatively in candidates for total hip replacement (THR). A total of 30 studies were analyzed, acquired under two conditions: (i) with the conventional clinical auxiliary device (control) and (ii) with the newly designed device (experimental).

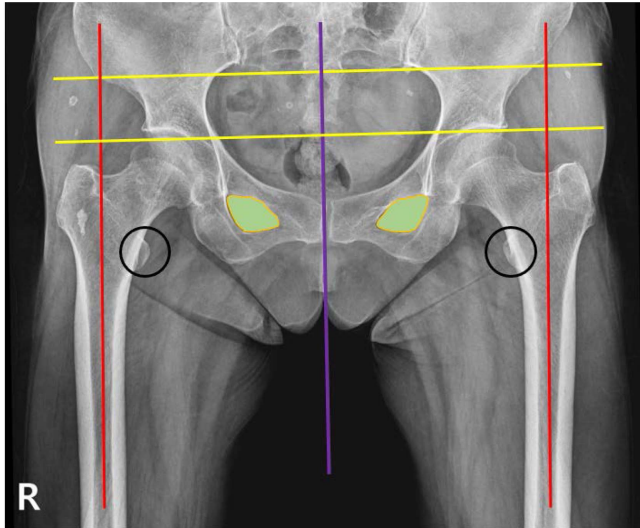
As shown in Table 2, Three outcome metrics were specified: (1) image alignment, which was assessed by central-ray congruence and bilateral symmetry; (2) the



**Fig. 1.** (Color online) Development process of the auxiliary device for pelvic and lower extremity X-ray examinations. (A) Assistive devices used in existing clinical practice, (B) 2D sketch concept, (C) 3D modeling design, (D) Processing materials (polycarbonate) and design drawings, (E) Finished product after assembling parts through CNC (computerized numerical control) milling.

**Table 1.** Questionnaire items by area to evaluate learning efficiency.

Evaluation Items	Evaluation Contents	Evaluation Method
Cognitive domain (knowledge comprehension, out of 10)	What is the leg position during a standard anteroposterior (AP) pelvic radiograph?	4 multiple choice questions (2 points each)
	Why should the femoral neck be internally rotated in anteroposterior (AP) radiographs of the pelvis?	
	Where is the center line (CR) aligned in an anteroposterior (AP) pelvic radiograph?	
	What is the main purpose of using an auxiliary device in anteroposterior (AP) pelvic radiography?	
Psychomotor domain (self-assessment of practical performance, n number)	What causes left-right asymmetry during anteroposterior (AP) pelvic radiography?	5-point Likert scale
	I was able to maintain the patient's positioning accurately.	
	Postural reproducibility was high during the examination.	
	The examination was stable.	
Affective domain (satisfaction and confidence, n number)	The patient's position angle was easily adjusted.	5-point Likert scale
	There were few errors or readjustments during the examination.	
	The examination process was easy to understand.	
	I believe the existing method can be applied in actual clinical practice.	
Comprehensive self-assessment	I felt confident in performing the examination techniques.	5-point Likert scale
	I believe the image quality will remain consistent.	
	I am satisfied overall with the learning method.	
	How did your learning experience improve before and after using the assistive device?	



**Fig. 2.** (Color online) Standard pelvic imaging evaluation criteria by X-ray examination. This examination indicates whether the line connecting the ASIS (anterior superior iliac spine) on both sides is parallel to the line connecting the femoral heads on both sides (yellow line), whether the femoral heads on both sides are aligned parallel (red line), whether the obturator foramen on both sides are symmetrical (green), whether the midline of the sacrum and the center of the symphysis pubis are aligned (purple line), and whether the lesser trochanter is obscured by the femoral shaft (black circle).

length of the lesser trochanter (lateral extent on AP projection) as an indicator of femoral rotational positioning; and (3) the number of exposures required to obtain a diagnostically acceptable pelvic measurement image. The details of the image evaluation and the corresponding scores are presented in Table 2.

All images were reviewed in a blinded fashion and independently scored by two radiographers with  $\geq 10$  years of clinical experience.

Radiographs were acquired using standardized exposure parameters (tube potential 70 kVp–80 kVp, tube load 20 mAs, source-to-image distance 100 cm). As shown in Fig. 2, Alignment was evaluated against predefined criteria for midline centering and right–left symmetry.

The image dataset comprised examinations obtained during routine clinical workflows in which the auxiliary device was used as part of standard clinical practice. No additional radiation exposure or subject intervention was required for the purposes of this study. All data were anonymized prior to analysis, and the study met the criteria for exemption from Institutional Review Board (IRB) review under Article 13 of the Republic of Korea Bioethics and Safety Act and Article 33 of its Enforcement Rule.

**Table 2.** Evaluation items, contents, and methods by field for medical image evaluation.

Evaluation Items	Evaluation Contents	Evaluation Method
Image alignment	Are the lines connecting the ASIS on both sides parallel to the lines connecting the femoral heads on both sides?	Qualitative medical image evaluation (100 points)
	Are the femoral heads on both sides aligned parallel to each other?	
	Are the obturator foramina symmetrical?	
	Does the midline of the sacrum coincide with the center of the symphysis pubis?	
	Is the lesser trochanter obscured by the femoral shaft?	
Projected width of the lesser trochanter	Length from the lesser trochanter to the lateral aspect of the femur (mm)	Quantitative image measurements (mm)
Number of exposures (n)	Number of pelvic measurement examinations	Number of quantitative exposures (n)

### 3. Results

#### 3.1. Fabrication and Integrated Application of the Auxiliary Device

The auxiliary device was designed and fabricated with the aim of enhancing postural reproducibility and alignment accuracy during pelvic and lower extremity radiography, emphasizing structural stability, angular adjustability, and user safety.

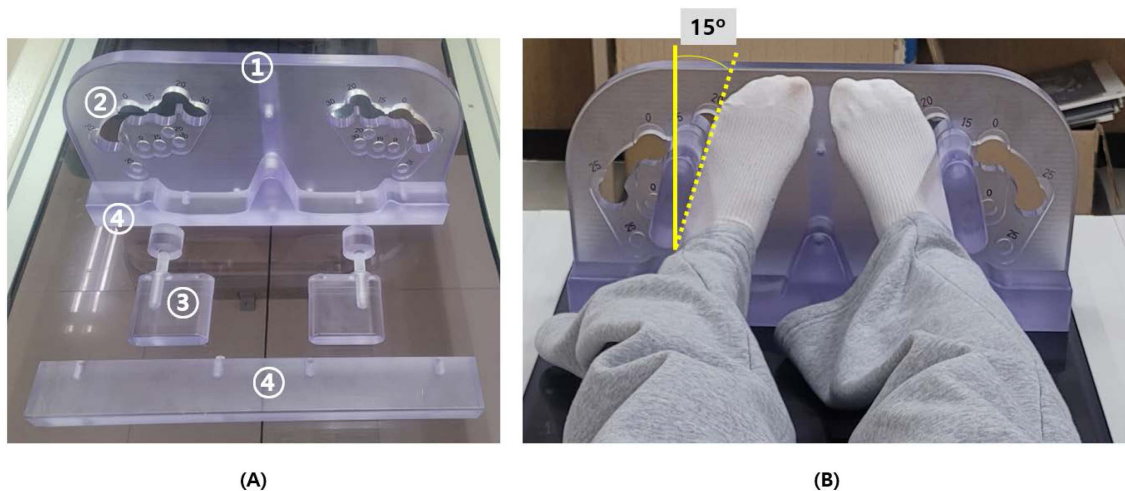
As shown in Fig. 3, the assembly comprises a main body frame, an angle adjustment module, a locking pin unit, and a lower extremity fixation unit. Polycarbonate was employed throughout to provide lightweight strength and transparency while improving pressure distribution at skin contact interfaces and reducing slippage during setup.

The core functionality, a multi-stage angular adjustment system, permits fine control across five preset positions

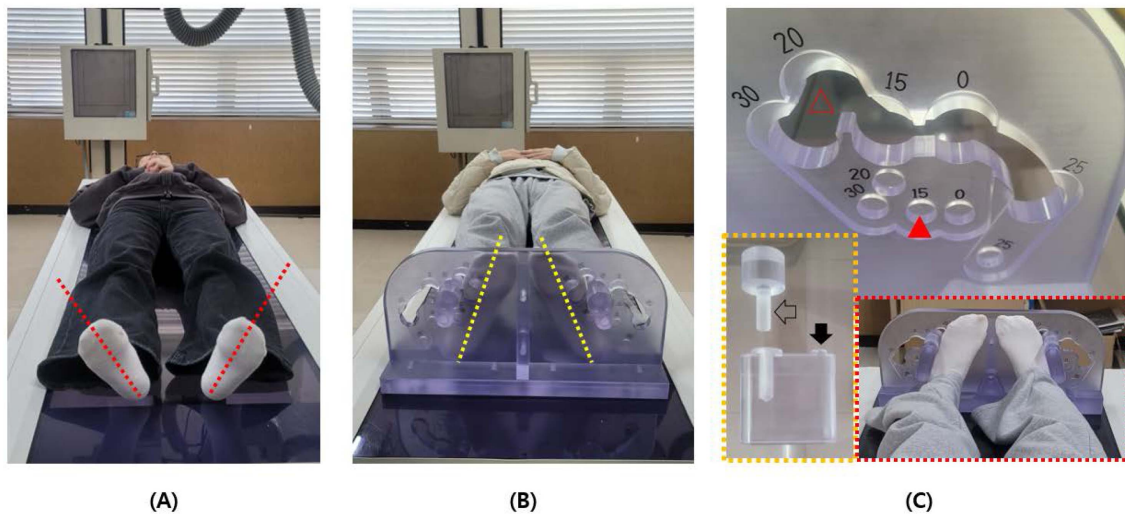
( $-30^\circ$ ,  $-20^\circ$ ,  $-15^\circ$ ,  $0^\circ$ ,  $+25^\circ$ ). As shown in Fig. 4(C), Position-specific fixation is achieved via circular grooves engaged by the locking pin; insertion and rotational securing of the pin follow a keyhole-type mechanism to ensure rapid, reproducible indexing. The device is modular to facilitate disassembly and cleaning. In a 100-cycle test of repeated component detachment and reattachment, no screw loosening or structural damage was observed.

#### 3.2. Educational Effectiveness and Clinical Efficiency

The structurally optimized auxiliary device was engineered to enhance patient postural reproducibility and radiographic alignment during pelvic and lower extremity X-ray examinations. Its educational effectiveness and clinical efficiency were then evaluated.



**Fig. 3.** (Color online) After assembling the development aid components, the foot angle is internally rotated and fixed in position. (A) ① Main torso frame, ② angle adjustment module, ③ locking pin unit, ④ lower overall extremity fixture; (B) The auxiliary device's foot angle is internally rotated 15 degrees (measured as the angle between the dotted line and the solid yellow line).



**Fig. 4.** (Color online) Foot angle and angle-marking imprint before and after using the auxiliary device. (A) The foot is externally rotated in its natural state (red dotted line inclined toward the longitudinal axis of the foot), (B) The foot is internally rotated in the auxiliary device (yellow dotted line inclined toward the longitudinal axis of the foot), (C) Same angle markings for the upper space (indicated by the red transparent triangle) and the lower groove (indicated by the solid red triangle) areas, (D) Identical angle markings of the upper space (indicated by the red transparent triangle) and lower groove (indicated by the solid red triangle) and the angle fixing screw (indicated by the black transparent arrow) and foot support (indicated by the solid black arrow, shown within the orange dotted rectangle), internal rotation of the foot fixed to the auxiliary device (shown within the red dotted square).

### 3.2.1. Evaluation of Learning Effectiveness

Pre- and post-training evaluations were administered to 15 radiologic science students who participated in laboratory sessions utilizing the auxiliary device. As shown in Table 3, In the cognitive domain, the mean knowledge-comprehension score increased from 9.2 to 9.33 (+0.13 points; ≈1.3%). In the psychomotor domain, the mean number of students providing positive responses regarding practical performance of pelvic positioning increased from 8.2 to 14.8 (≈44% per the study rubric). In the affective domain (encompassing satisfaction and confidence), positive responses increased from 11.0 to

14.8 (≈25.4%). These results indicate that the proposed aid enhances visual-tactile understanding and provides substantive support for the reproducible learning of radiographic positioning. Table 3 and Fig. 5 show comparative measurement values and graphs.

### 3.2.2. Evaluation of Clinical Efficiency

Across 30 clinical examinations, imaging alignment accuracy and acquisition efficiency were compared between the conventional clinical aid (control) and the newly designed device (experimental). As shown in Table 3, Image alignment averaged 81.4 in the control cohort

**Table 3.** Comparison of Learning Effects by Area and Medical Imaging Evaluation Results by Region Between the Control and Experimental Groups.

Evaluation Method	Control Group (n = 15)	Experimental Group (n = 15)	Improvement in Learning & Relative Change (%)
Cognitive domain (knowledge comprehension, out of 10)	9.2	9.33	1.3
Psychomotor domain (self-assessment of practical performance, n number)	8.2	14.8	44
Affective domain (satisfaction and confidence, n number)	11	14.8	25.4
Image alignment (score)	81.4	82.6	1.5
Length of lesser trochanter (mm)	6.57	6.31	-4.0
Number (n)	3.67	2.20	-40.1

Comparison of learning effects before and after using auxiliary devices

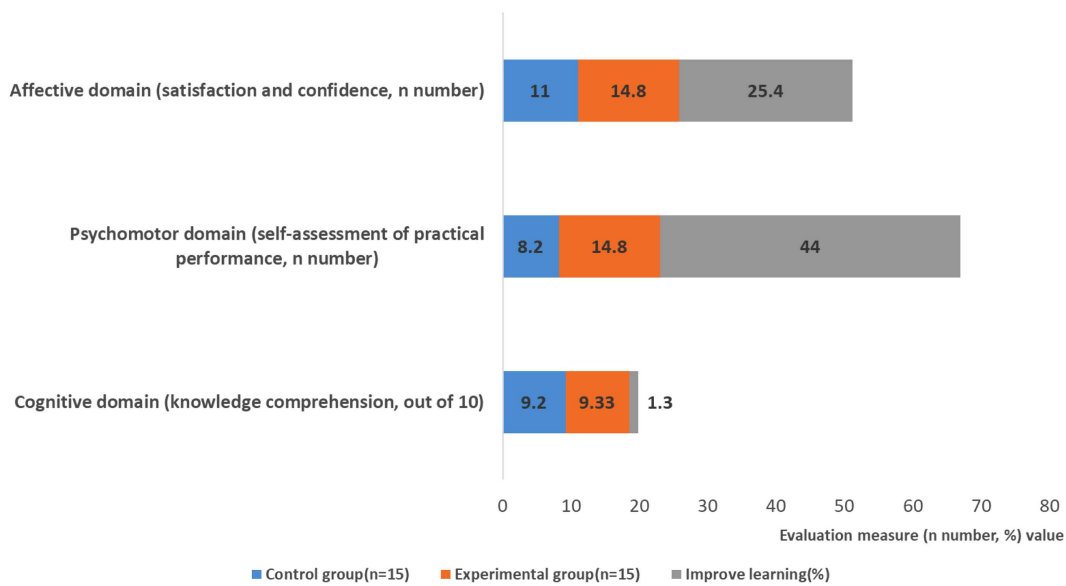


Fig. 5. (Color online) Comparison graph of learning effects before and after using assistive devices.

and 82.6 in the experimental cohort, reflecting a +1.5% improvement. The projected width of the lesser trochanter measured 6.57 mm (control) versus 6.31 mm (experimental), a -4.0% reduction indicative of improved femoral rotational positioning. The number of exposures required to obtain a diagnostically acceptable pelvic

measurement image decreased from 3.67 (control) to 2.20 (experimental), representing a 40.1% reduction. Collectively, these findings indicate that the device under evaluation enhances alignment performance while substantially improving acquisition efficiency. Table. 3 and Fig. 6 show comparative measurement values and graphs.

### 3.2.3. Integrated Analysis

During the training phase, the device’s structural stability and angular adjustability facilitated reproducible practice of standardized positioning. In the clinical phase, improvements were observed in acquisition efficiency and image-alignment accuracy. Notably, the circular-groove interface and locking-pin mechanism enhanced the repeatability of lower extremity fixation, thereby mitigating image-quality variation attributable to inter-operator differences in experience. Collectively, these findings support the utility of the developed auxiliary device as an educational tool and indicate its potential to contribute to higher and more consistent radiographic quality in clinical application.

Comparison of medical image evaluation

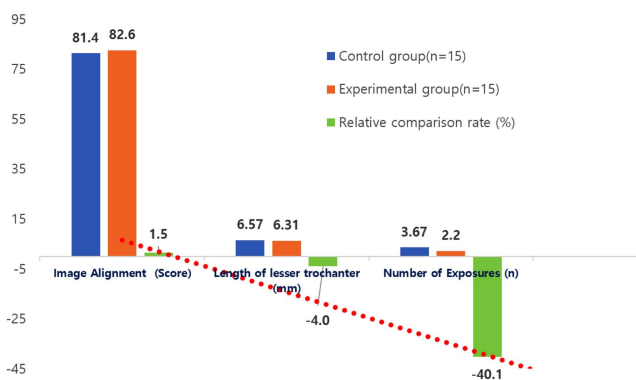


Fig. 6. (Color online) Comparison of the number of exposures before and after using the auxiliary device. The bar graph compares the control group (blue) and the experimental group (orange), with the trend line (red dashed line) representing the difference between the two groups (green bars). As a result, the experimental group showed a 1.5% higher image alignment accuracy, a 4% reduction in the lesser trochanter diameter, improved pelvic accuracy, and a 40.1% decrease in the number of examination exposures, indicating enhanced pelvic precision and a lower retake rate.

## 4. Discussion

This study addressed the challenge of achieving reproducible patient positioning and standardized projection geometry in pelvic and lower extremity radiography by designing a structurally optimized auxiliary device and evaluating its educational and clinical efficiency. The developed device provided five preset angular positions

( $-30^\circ$ ,  $-20^\circ$ ,  $-15^\circ$ ,  $0^\circ$ ,  $+25^\circ$ ), enabling precise posture configuration under diverse imaging conditions and contributing to improved image consistency and reproducibility. In particular, a circular-groove, locking-pin mechanism supported stable angle maintenance during repeated use. The five-step, multi-angle architecture was conceived to facilitate applicability to additional radiographic examinations requiring controlled angular variation.

The polycarbonate frame, selected for its low weight, transparency, and dimensional stability, together with an intuitive operating interface, demonstrated high usability in both clinical and educational contexts [13, 14]. These characteristics promoted visual–tactile comprehension of posture control and beam–anatomy relationships, thereby extending beyond theory-centered instruction to tangible enhancement of hands-on skills.

Previous studies have reported that positioning aids for lower extremity radiography are primarily designed with fixed structures or are limited to single joint regions, such as the knee or ankle, which restricts their ability to comprehensively assess overall lower limb alignment [15, 16]. In contrast, the positioning aid developed in this study incorporates a multi-angle adjustable structure that considers the alignment of the entire lower extremity, including the pelvis, thereby achieving both reproducibility of imaging angles and stability of patient positioning. These findings suggest that the proposed device extends the limited applicability of conventional positioning aids and enables more standardized acquisition of lower limb alignment radiographs.

Clinically, the aid reduced positioning error across repeated acquisitions, fostered standardization of image quality, and yielded a practical reduction in the projected width of the lesser trochanter ( $-4\%$ ), consistent with improved femoral rotational alignment. Moreover, the number of exposures required to obtain a diagnostically acceptable pelvic measurement image decreased by approximately 40%, implying potential mitigation of gonadal radiation risk during pelvic examinations.

From an educational standpoint, the device functioned as a high-value laboratory tool that enabled experiential learning of X-ray principles, the primacy of posture, and sources of geometric distortion. In the training cohort, positive changes were observed in self-rated practical performance ( $+44\%$ ) and in satisfaction/confidence ( $+25.4\%$ ), supporting the pedagogical utility of the device for competency-based skills acquisition.

However, several limitations warrant consideration: the sample size was modest, the learning assessment focused on pelvic and lower extremity positioning, and the clinical analysis employed a retrospective review of pelvic

measurement studies performed at a single university hospital. Future research should include prospective, quantitative comparisons of image quality and alignment metrics in broader patient populations, with subgroup analyses across body habitus and pathological conditions to evaluate generalizability.

## 5. Conclusion

In this study, a structurally optimized, multi-angle adjustable assistive device was developed to improve posture reproducibility and image quality in pelvic and lower extremity X-ray examinations, and its educational and clinical effectiveness was evaluated. Application of the device led to improvements in learners' practical performance and satisfaction, while clinical assessments demonstrated enhanced image alignment accuracy and a reduction in the number of exposures. These findings suggest that the proposed assistive device provides a valuable foundation for radiographic standardization and can be effectively applied in both educational and clinical settings.

## Acknowledgments

This work was supported by the Gimcheon University Research Grant of 2025 (gc25005).

## References

- [1] B. P. Selby, G. Sakas, W.-D. Groch, and U. Stilla, *Australas. Phys. Eng. Sci. Med.* **34**, 391 (2011).
- [2] Y.-L. Wang, C.-H. Lee, H.-Y. Chen, J.-S. Lin, and W.-C. Huang, *J. Funct. Morphol. Kinesiol.* **10**, 23 (2025).
- [3] C. Lopes, F. Silva, R. Pereira, and P. Santos, *Phys. Eng. Sci. Med.* **46**, 45 (2023).
- [4] J. Chung, H. Kim, S. Lee, and M. Park, *Biomed. Res. Int.* **2022**, 1057227 (2022).
- [5] J. W. Gil and Y. G. Kim, *J. Korea Saf. Manag. Sci.* **17**, 223 (2015).
- [6] B. Zampogna, M. Vasta, S. Papalia, G. Torre, and V. Denaro, *Iowa Orthop. J.* **35**, 49 (2015).
- [7] S. Han, H. Lee, J. Kim, and K. Park, *J. Korean Soc. Radiol.* **77**, 263 (2017).
- [8] W. Chen, L. Zhang, M. Li, and H. Zhao, *J. Innov. Med. Res.* **3**, 45 (2024).
- [9] S. Kumar, L. Moro, and Y. Narayan, *Int. J. Ind. Ergon.* **33**, 29 (2004).
- [10] J. Considine, R. Z. Shaban, K. Curtis, and M. Fry, *Eur. J. Emerg. Med.* **26**, 314 (2019).
- [11] S. Henderson, H. Skelton, and P. Rosenbaum, *Dev. Med. Child Neurol.* **50**, 89 (2008).

- [12] A. L. Lenz, J. R. LaPrade, M. F. Turnbull, and T. L. Wijdicks, *Skeletal Radiol.* **48**, 1581 (2019).
- [13] Y. S. Ji, J. H. Kim, and M. S. Han, *J. Magn.* **28**, 449 (2023).
- [14] D. Y. Kim and S. S. Yoon, *J. Korean Magn. Soc.* **29**, 214 (2019).
- [15] T. Maruyama and H. Yamamoto, *Positioning* **4**, 289 (2013).
- [16] C.-C. Kuo, H.-Y. Lin, Y.-J. Wang, and P.-C. Chen, *Biomed. Eng. Online* **12**, 131 (2013).